

Effect of the combination of AREDS2 formulation and a polyphenol preparation on dry age-related macular degeneration: analysis of case studies



¹Robert T. McHugh, O.D., ²Jack L. Hollins, M.D., ³Francis C. Lau, Ph.D. and ³Bruce P. Daggy, Ph.D.
¹McHugh Optometry, Morehead, KY; ²Hollins Ophthalmology, Lexington, KY; ³Shaklee Research Center, Pleasanton, CA



BACKGROUND AND OBJECTIVES

Age-related macular degeneration (AMD) is a leading cause of blindness worldwide with limited pharmaceutical and surgical treatment options. In the United States, more than 50% of all blindness is caused by AMD. AMD is characterized by damage to the macula, a region of the retina. The etiology of AMD is largely unclear but it is associated with aging and other risk factors including genetics, hypertension, cardiovascular disease, obesity, and smoking. Nutrient-based preventive treatments for AMD have been evaluated in age-related eye disease study (AREDS) and AREDS2. AREDS2 formulation has been shown to significantly reduce the risk of developing advanced AMD. Case studies indicate that remission of AMD, though rare, does occur spontaneously. In this regard, retinal regeneration is possible. The purpose of the current study was to investigate the effects of combining AREDS2 treatment with a resveratrol/polyphenol-enriched supplement (RPS) on macular structure and visual function in dry AMD patients.

METHODS

Study design: clinical case studies.

Subjects: Patients (n=34, 8M/26F, mean age 73, range 56-85) with dry AMD.

Supplementation: AREDS2 plus RPS (5 mL/day) for at least four months.

Assessments: self-reported vision and Snellen acuity, OCT scan of maculae, and fundus photos before and after treatments.

Table 1. Summary of % improvement in vision and macular structure

Assessments	Improvement (%)
Improved vision of at least one line, Snellen acuity	44.1
Improved vision and reduction in size and number of macular drusen	14.7
Decrease in size and number of drusen	26.5
Improved contour of macula	8.8
No change in vision or drusen	23.5
Reduction in visual acuity	0

The effects of AREDS2 + RPS combination on visual/structural improvements in AMD patients were summarized in Table 1:

- 15 patients experienced improved vision of at least one line of Snellen acuity test (44.1%).
- 5 patients showed improved vision and reduction in size and number of macular drusen (14.7%).
- 9 patients exhibited reduction in size and number of drusen (26.5%).
- None of the patients showed decreased visual acuity.
- 8 patients did not show any change in vision or drusen (23.5%).

Figure 1.

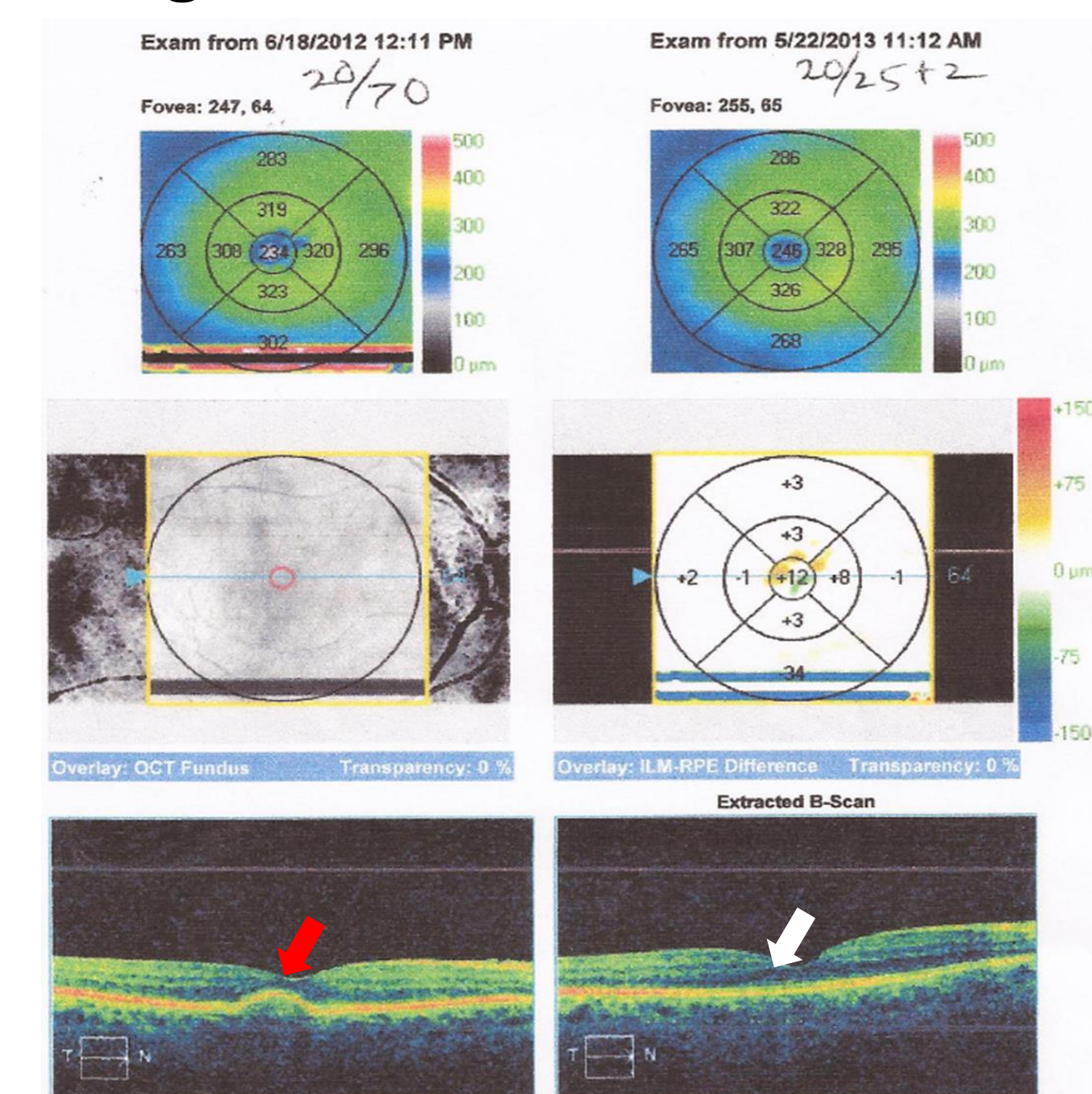


Figure 1. *Case 1.* A 67 year old female in good health has a history of a damaged left eye from trauma with no central vision and dry macular degeneration with soft drusen in her right eye. The dry AMD has been evident with no changes for about 3 years. She then noticed a gradual decrease in vision over a 4 month period. Her vision had decreased from 20/30 to 20/70 Snellen. A consult with two retinal specialist ophthalmologists confirmed the AMD to be dry. This patient had faithfully taken her AREDS formulation. After taking 5 mL per day of RPS in addition to the vitamins for 4 months, her vision returned to 20/30 and the large drusen (red arrow) that was distorting her retina disappeared (white arrow). After about 11 months her vision improved 5 Snellen lines to 20/25+.

Figure 2.

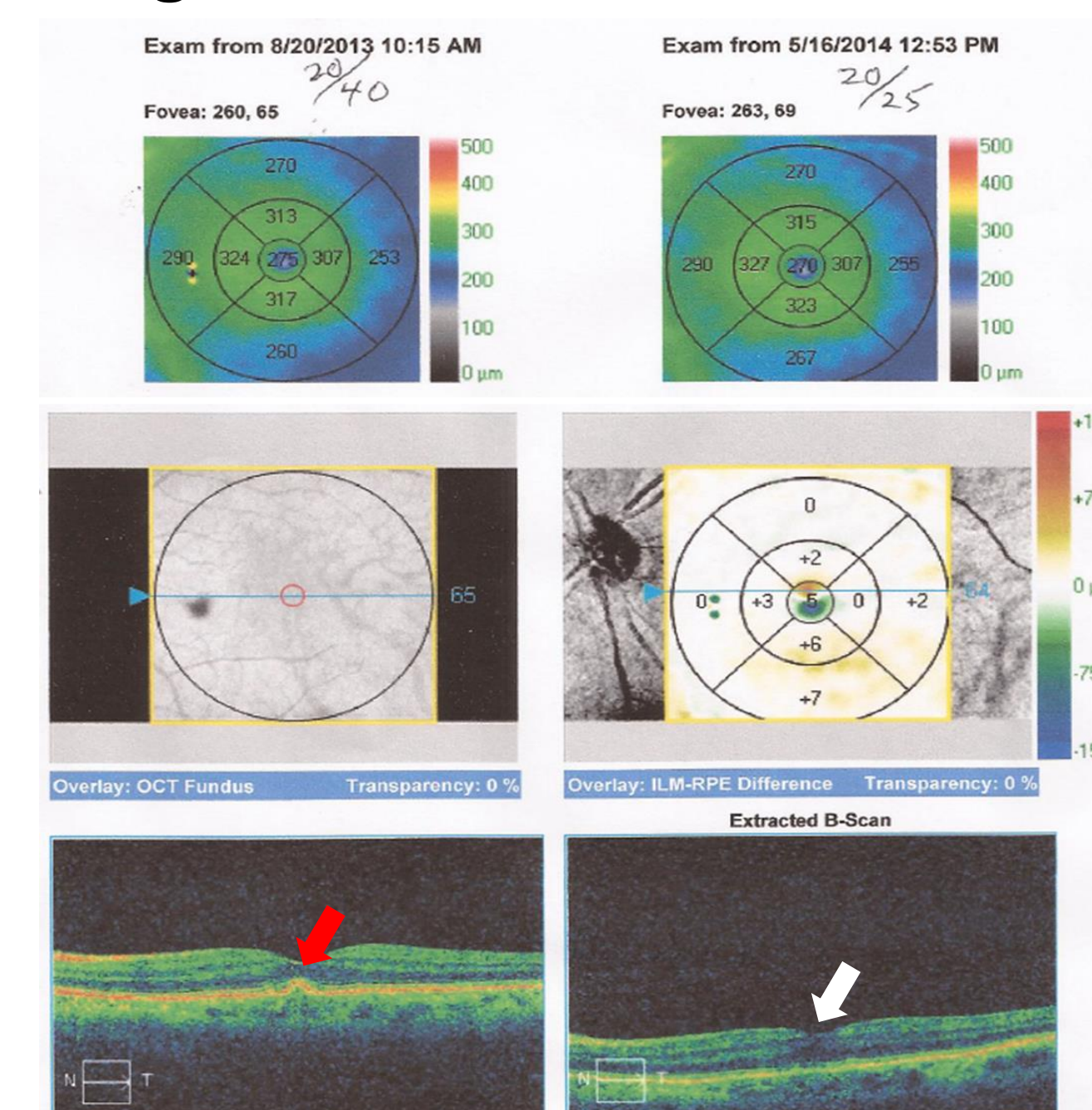


Figure 2. *Case 2.* An 83 year old female in good general health, who has had dry macular degeneration in the form of soft drusen (red arrow) in both eyes for about 5 years, and who has taken her AREDS formula faithfully for 5 years. After 9 months of taking 5 mL of RPS per day in addition to AREDS formulation, she showed improved vision as measured in Snellen acuity of 2 lines and a reduction in drusen (white arrow) in her left eye.

RESULTS

Figure 3.

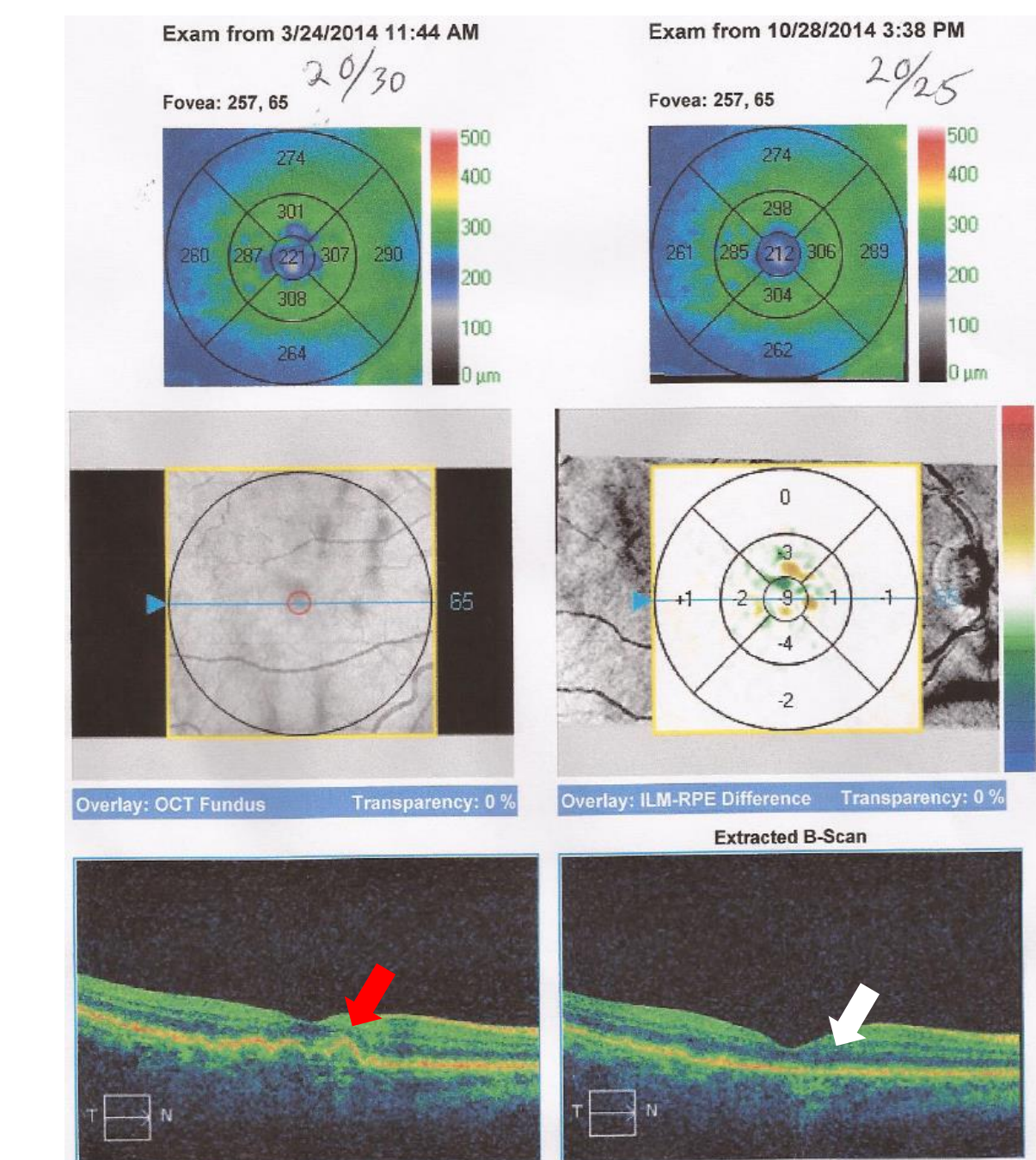


Figure 3. *Case 3.* A 71 year old female with type two diabetes but otherwise good health. She had dry AMD and drusen (red arrow). After taking AREDS formulation for over two years and 5 mL of RPS per day for one year, she displayed improved vision from 20/30 to 20/25 and decreased drusen with increased integrity of the retinal pigment epithelium (white arrow).

Figure 4.

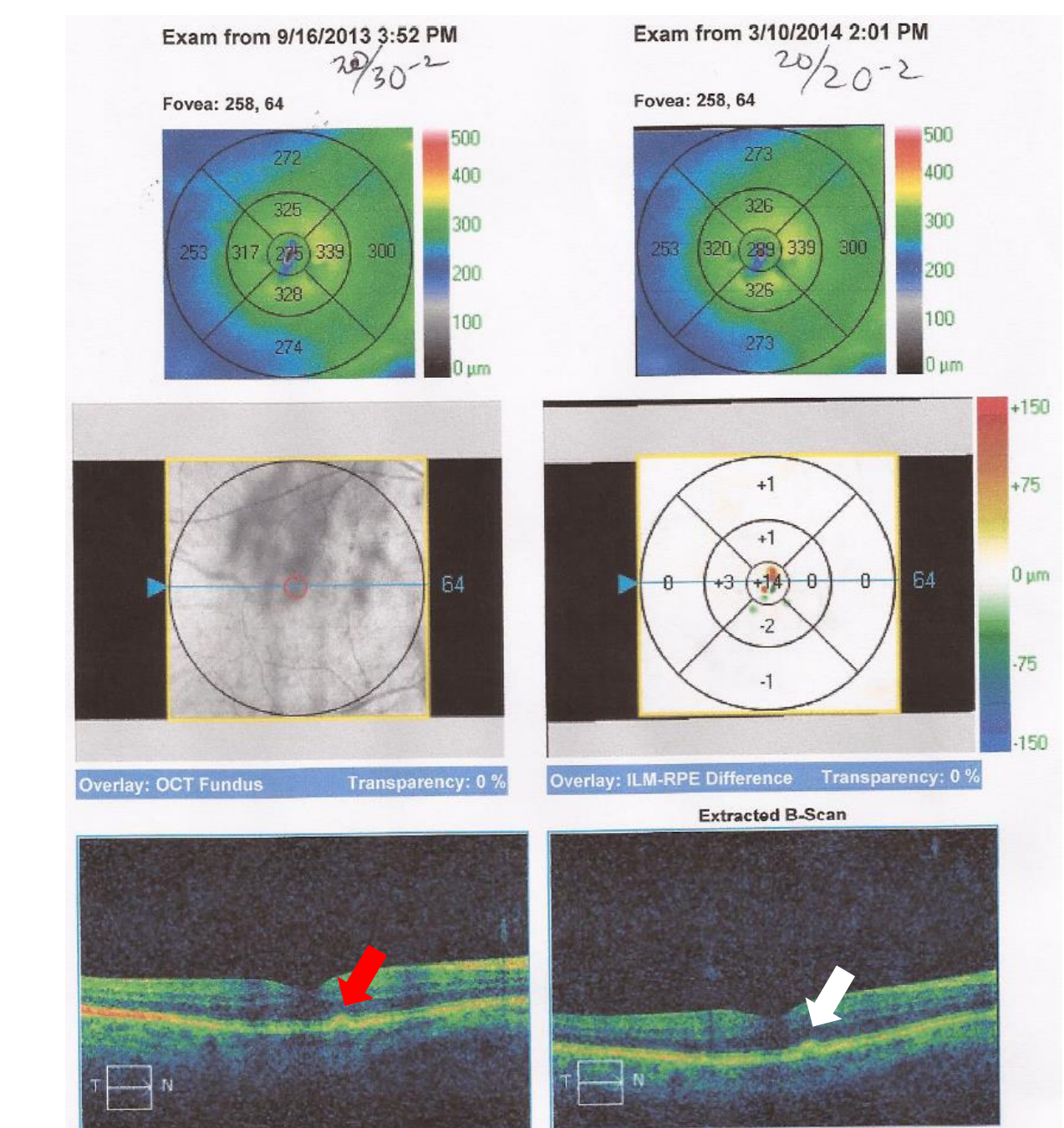


Figure 4. *Case 4.* A 66 year old male with high cholesterol but otherwise in good health. He was diagnosed with dry AMD and drusen (red arrow). After taking AREDS formulation along with 5 mL RPS per day for 6 months, he showed improved vision from 20/30 to 20/20 and integrity and uniformity of the retinal pigment epithelium (white arrow).

SUMMARY

Supplementation with AREDS2 plus RPS improved vision by at least one line in Snellen acuity in 44% of the participants. Reduction in size and number of drusen was observed in 26.5% of the patients and improvement in contour of macula was seen in 8.8% of the patents. No reduction in visual acuity was recorded after supplementation. 23.5% of the patients had no change in vision or number of drusen.

CONCLUSIONS

Overall, supplementation with AREDS2 plus RPS for at least four months resulted in structural and/or visual improvements in approximately 70% of patients. The limitations of these case presentations are that the observations do not distinguish between the possibilities that the effects of the polyphenol preparation on retinal structure/function depend on synergistic interactions with AREDS2, or if the polyphenols alone are responsible. Future randomized, placebo-controlled clinical trials are warranted to confirm the beneficial effects of RPS alone and in combination with AREDS2 formulation in the treatment of dry AMD.